

Antiatherosclerotic potential of aliskiren: its antioxidant and anti-inflammatory effects in rabbits: a randomized controlled trial

Hayder A Al-Aubaidy^{1*}, Hussien A Sahib², Bassim I Mohammad², Najah R Hadi³ and Shoroq M Abas⁴

*Correspondence: halaubaidy@csu.edu.au

¹Biomedical Science Discipline Leader, Health and Rehabilitation Science Course Coordinator, School of Community Health, Centre for Research in Complex Systems, Charles Sturt University, NSW, Australia.

²Department of Pharmacology, College of Medicine, Al Qadisiyah University, Iraq.

³Department of Pharmacology, College of Medicine, Kufa University, Iraq.

⁴Department of Pathology, College of Medicine, Al Qadisiyah University, Iraq.

Abstract

Background: Aliskiren is a direct renin inhibitor. It counteracts renin-angiotensin system and is used to treat hypertension. This study aims to evaluate the effect of aliskiren on the progression of atherosclerosis in domestic rabbits.

Methods: Twenty-one local domestic rabbits were divided into three groups each group had special dietary regimen for 8 weeks: Group I (normal control), Group II (atherogenic control) and Group III (2% Cholesterol + aliskiren 40mg/kg/day orally). Blood samples were collected at the end of experiment (8 weeks) for measurement of serum lipid profile, plasma high sensitive C-reactive protein (hs-CRP), plasma malondialdehyde (MDA) and plasma reduced glutathione (GSH). Immunohistochemical analysis including vascular cell adhesion molecule-1 (VCAM-1); monocyte chemoattractant protein-1 (MCP-1); tumor necrotic factor - α (TNF- α); and interleukin - 17 (IL-17). Histopathologic assessment of aortic atherosclerotic changes were also performed.

Results: Compared to normal control group, there is a significant increase in the level of lipid profile, hs-CRP (134.1 \pm 1.2ug/L), and malondialdehyde (0.561 \pm 0.136umol/L) in the atherogenic diet group, while GSH was significantly reduced (0.58 \pm 0.024mmol/L) at ($p \leq 0.05$). Immunohistochemical analysis showed that expression of aortic VCAM-1; MCP-1; TNF- α ; and interleukin-17 were significantly increased in atherogenic control group compared to normal control group ($p < 0.001$). In addition, animals on atherogenic diet have significant atherosclerotic lesion compared to normal control group. Aliskiren group appears to have no significant effect on lipid profile compared to atherogenic control group, but it has statistically significant reduction in hs-CRP (73.1 \pm 3.88ug/L) and MDA (0.261 \pm 0.15umol/L) at ($p \leq 0.05$). Aliskiren treatment failed to significantly increase the level of plasma reduced glutathione. In addition, aliskiren treatment significantly reduced the expression of VCAM-1; MCP-1; TNF- α ; and IL-17 ($p \leq 0.05$). Histopathological examination of aortic arch showed that aliskiren significantly reduced atherosclerotic lesion ($p \leq 0.005$).

Conclusion: We can conclude that aliskiren is helpful in reducing lipid peroxidation, systemic inflammation and aortic expression of inflammatory markers used in this study and hence reduces the progression of atherosclerotic plaque.

Keywords: Atherosclerosis, aliskiren, oxidative stress, antioxidant, inflammatory markers

Introduction

It is well established that atherosclerosis is a disease of large and medium-sized arteries that is characterized by endothelial dysfunction, vascular inflammation, and the build up of lipids, cholesterol, calcium, and cellular debris within the intima of the vessel wall [1]. Gerard *et al.*, in 2001 proved that the atherosclerotic plaque composition, (rather than stenosis severity), is the most important determinant for the thrombus-mediated acute coronary syndromes [2], that is initiated by endothelial dysfunction and followed subsequently by inflammatory cells infiltration of the vascular wall [3]. Immune cells dominate early in atherosclerotic lesions, their effectors molecules accelerate progression of the lesions, and activation of inflammation can elicit acute coronary syndromes [4].

Hypercholesterolemia causes infiltration and retention of LDL in the arterial intima [5], these retained LDL become modified

(aggregated and oxidized) and initiate an inflammatory response in the arterial wall by inducing endothelial cell dysfunction and smooth muscle proliferation, in addition this modified LDL up-regulates the expression of leukocyte adhesion molecules (vascular cell adhesion molecule-1 and E/P-selectin), as well as other chemokines, such as macrophage colony stimulating factor (M-CSF) and monocyte chemoattractant protein-1 (MCP-1) in the endothelial cell [5,6]. This causes the monocytes to prematurely enter the subendothelium, differentiate into macrophages, up-regulate the expression of scavenger receptors (SRs), and ingest the retained and modified LDL to become cholesterol-laden foam cells [7,8]. Smooth muscle cells (SMCs) migrate into the intima and promote formation of a collagenous fibrous cap, probably representing a scar-like response to wall off the lesion, as the lesion progresses, macrophages die and eventually give rise to areas of necrosis filled with extracellular

debris, cholesterol crystals, proteases, and procoagulant / thrombotic material [7].

The renin-angiotensin aldosterone system (RAS) has emerged as one of the essential links in the pathophysiology of vascular disease. Angiotensin II (Ang II), the main peptide of RAS, produces chemokines, cytokines, and adhesion molecules, which contribute to the migration of inflammatory cells into the tissue injury [9]. Aliskiren is an orally active non-peptide direct renin inhibitor (DRI). It binds to the active site of renin and inactivates it [10]. Aliskiren is rapidly absorbed orally with maximal concentrations reached after 1–3 hours. It is circulated unchanged in plasma and excreted mainly via the biliary route. Aliskiren has a long half-life and is therefore suitable for once-daily dosing [11]. Previous studies showed the benefits of aliskiren on improving the blood pressure and reduces the incidence of atherosclerosis [12,13], still more studies are required to clarify the major clinical endpoints of aliskiren. Present study was undertaken to evaluate the effect of aliskiren on the progression of atherosclerosis.

Materials and methods

Animals

A total of 21 local domestic rabbits, weighing (1.1-1.5) kg, were used in this study. All experiments were conducted in the Department of Pharmacology, College of Medicine, Qadaysia University and approved by the University's Animal Ethics Committee, according to the guidelines for the Care and Use of Laboratory Animals in scientific research. The animals were placed in an animal house, in a group caging system, at controlled temperature ($25\pm 2^{\circ}\text{C}$) and ambient humidity. Lights were maintained on a 12-h light/dark cycle. The animals had free access to water *ad libitum*.

Drugs

Aliskiren was used in a dose of 40 mg/ kg orally. A 300 mg tablets (Novartis, Batch No. S0102) was dissolved in distilled water, and given to the rabbit according to the body weight once daily by stomach tube [12].

Animal model of atherosclerosis

Induction of atherosclerosis was carried out by feeding the rabbit an atherogenic diet (2% cholesterol (BDH Chemicals Ltd Poole England, prod 43011) enriched rabbit chow) [14,15] made by addition of cholesterol powder to chow pellets for 8 weeks.

Experimental Protocol

After 2 weeks of acclimatization period, the animals randomized into 3 groups (of 7 rabbits each): Normal diet control group (NC, group I), high-cholesterol diet group which served as atherogenic control (AC, Group II), and high-cholesterol diet with aliskiren group (AT, Group III) The NC group was fed normal rabbit chow, whereas the high cholesterol diet groups were fed a 2% high-cholesterol

(atherogenic) diet. The duration of treatment was 8 weeks. At the end of the experiment, food was withheld for 16 hours and animals were anesthetized by ketamine (HIKMA pharmaceuticals B.N 3310) at 66 mg/kg and xylazine (alfasan B.N 1004111-07) at 6 mg/kg intramuscularly [16]. The chest was opened by thoracotomy, blood sample was collected directly from the heart and aorta was separated before following investigations were performed:

1. Serum Lipid profiles including total serum cholesterol (TC), triglycerides (TG), low density lipoprotein-cholesterol (LDL-C), and high density lipoprotein cholesterol (HDL-C).
2. Immunohistochemistry for assessment of vascular cell adhesion molecule-1 (VCAM), tumor necrotic factor - α (TNF- α); and interleukin - 17 (IL-17), and monocyte chemoattractant protein-1 (MCP1).
3. Oxidation parameters including malondialdehyde (MDA) as a marker of lipid peroxidation and reduced glutathione (GSH) as an antioxidant marker.
4. Systemic inflammatory marker, plasma high sensitive C-reactive protein (hs-CRP)
5. Histopathological examination of the aorta for assessment of atherosclerosis.

All specimens were immediately fixed in 10% formaldehyde solution for subsequent processing.

Biochemical Procedures

Serum lipid profiles were determined by enzymatic methods using an automatic analyzer (Abbott, Alcyon 300, USA). Plasma GSH level was determined using methods of Beutler [17]. Plasma MDA level was determined using competitive inhibition enzyme immunoassay technique (cusabio; Catalog No. CSB-E13712Rb). Determination of hs-CRP was done by using rabbit high-sensitive C-reactive protein (CRP) ELISA kit supplied by (Kamiya Biomedical Company; Cat. No. KT-097). The measurement was carried out according to the manufacturer's instructions.

Histological examination of the aorta

For histological evaluation of atherosclerosis, the specimens were processed in usual manner, and embedded in paraffin and cut into 5 μm thick sections. The tissue sections were stained with hematoxylin and eosin. The assessment of atherosclerotic changes was performed according to the American Heart Association classification of atherosclerosis; Type I and Type II lesions (early lesions), Type III lesions (intermediate lesions or preatheroma), Type IV lesions (atheroma), Type V lesions (fibro-atheroma or advance lesion) and Type VI (complicated lesion) [18].

Immunohistochemistry

Immunohistochemistry was performed with polyclonal goat antibodies, raised against rabbit VCAM-1, TNF- α , MCP-1 and IL-17. Staining procedure was carried out according to the manufacturer's instructions (Santa Cruz Biotechnology, Inc).

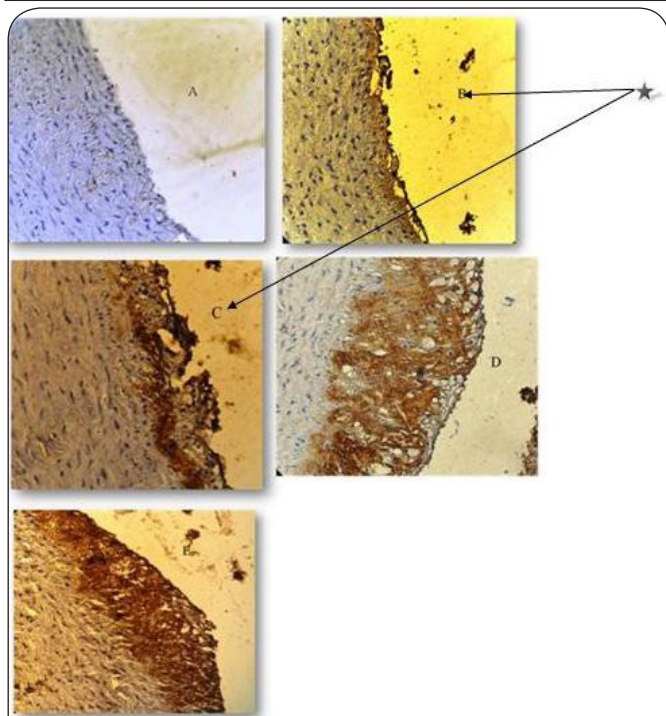


Figure 1. Showing different scores for the immunohistochemical stain intensity: A (negative stain), B (weak stain intensity), C (moderate stain intensity), D (strong stain intensity), E (very strong stain intensity).
 ★ Aliskiren treated group was associated with a median stain intensity of moderate for VCAM-1 (C) and weak for MCP-1, IL-17 and TNF-alpha (B).

Table 1. Change in serum lipid profile in the normal control (NC), atherogenic control (AC) and aliskiren treated (AT) groups, expressed as mean ± SEM.

Parameters	Groups		
	NC	AC	AT
TC (mg/dl)	46.3±0.99	1255±83.06*	1092.1±69.68
TG(mg/dl)	60±3.47	431±84.28*	365.9±61.46
HDL-C (mg/dl)	15.7±1.46	22.4±2.17*	23.3±3
LDL-C (mg/dl)	18.6±1.46	1145±90.63*	1018±61.38
VLDL-C (mg/dl)	12±0.69	86.8±7.77*	53.2±12.29

*p < 0.05, AC compare to NC group.

The stain intensity was scored to 0: Indicated no staining, 1: Weak, 2: Moderate, 3: Strong, 4: Very strong stain intensity [19] (Figure 1).

Statistical analysis

Statistical analysis was performed using Statistical Product and Service Solutions (SPSS) version 14.0 and Microsoft Excel (Office2007, Microsoft). Data were expressed as mean ± SEM. Paired t-test was used to compare the mean values within each group at different time. Analysis of Variance (ANOVA) was used for the multiple comparison among all groups. The

Table 2. Change in mean plasma levels of hs-CRP, MDA and GSH in the normal control (NC), atherogenic control (AC) and aliskiren treated groups (AT), expressed as mean ± SEM.

parameters	Groups		
	NC	AC	AT
Plasma GSH (mmol/L)	1.114±0.0338	0.58±0.024*	0.618±0.0262
Plasma MDA(µmol/L)	0.129±0.66	0.561±0.136*	0.261±0.15**
Plasma hs-CRP (µg/L)	33.3±0.78	134.1±1.2*	73.1±3.88**

*p < 0.05, AC compare to NC group.

**p < 0.05, AT group compared to AC group.

histopathological grading was assessed by Mann-Whitney test. In all tests, P < 0.05 was considered to be statistically significant.

Results

Effect of high cholesterol diet

Compared to NC group, rabbits fed on cholesterol-enriched diet showed significant changes in serum TC (1255±83.06 mg/dl (group II or AC) vs. 46.3±0.99 mg/dl (group I)), TG (431±84.28 mg/dl (group II) vs. 60±3.47 (group I)) and LDL-C (1145±90.63 mg/dl (group II) vs. 18.6±1.46 (group I)) compare to the NC group at p ≤ 0.05, see Table 1.

Also, there was an increased oxidative stress and inflammatory markers in that group as presented with marked reduction in GSH (0.58±0.024 mmol/L (group II) vs. 1.114±0.0338 mmol/L (group I)), associated with marker elevation in MDA (0.561±0.0136 umol/L (group II) vs. 0.129±0.66 umol/L (group I)) and plasma hs-CRP (134.1±1.2 ug/L (group II) vs. 33.3±0.78 ug/L (group I)) in the AC compared to the NC at p ≤ 0.05, Table 2.

Effects of aliskiren treatment

Compared to atherogenic control, treating hyperlipidemic rabbits with aliskiren resulted in significantly lower levels of plasma hs-CRP (73.1±3.88 ug/L (group III) vs. 134.1±1.2 ug/L (group II)) and MDA (0.261±0.15 umol/L (group III) vs. 0.561±0.136 umol/L (group II)) in the AT group compared to the AC group, P≤0.01). However aliskiren treatment did not significantly alter serum lipids and GSH levels, (Table 1 and Table 2).

Immunohistochemistry

The result of immunohistochemical analysis for rabbit's aortic arch of VCAM-1, MCP-1, IL-17 and TNF-alpha were significantly different between all the 3 study groups. The median intensity of these markers was highest in AC group (very strong for all markers) and lowest in NC group (normal for all markers). Aliskiren treated group was associated with a median stain intensity of moderate for VCAM-1 and weak for MCP-1, IL-17 and TNF-alpha that is significantly lower than the atherogenic control, Table 3.

Histopathological findings

The atherosclerotic lesions of aortic arch were graded as

Table 3. The difference in median tissue (VCAM-1, MCP-1, TNF alpha and IL-17) immunostain intensity between the 3 study groups.

Markers	Groups		
	NC	AC	AT
VCAM-1	Negative	+++*	++**
IL-17	Negative	+++*	++**
MCP-1	Negative	+++*	++**
TNF- α	Negative	+++*	++**

+: Weak; ++: Moderate; +++: Very Strong

* $p < 0.05$, as compare to NC group.

** $p < 0.05$, as compare to AC group.

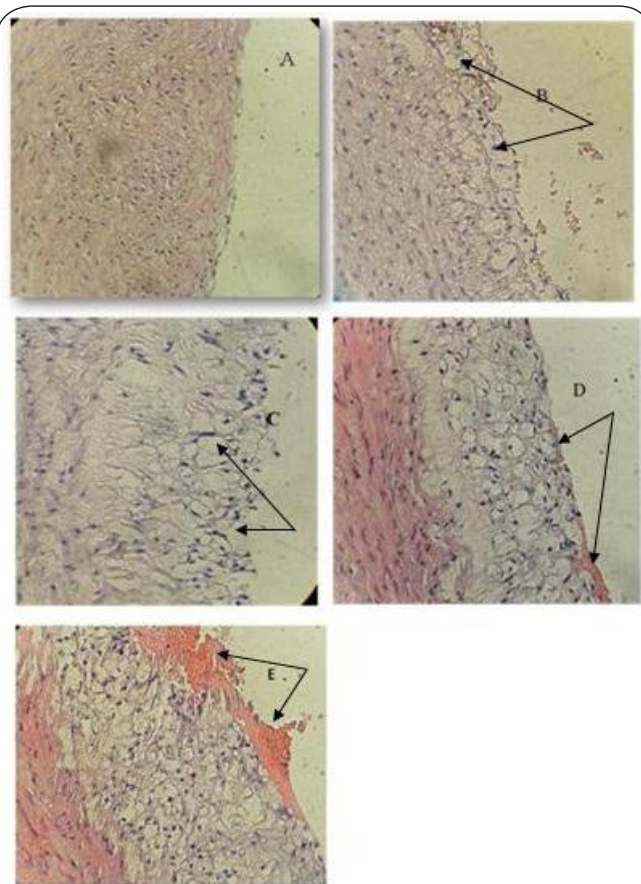


Figure 2. A cross section of aortic arch from hypercholesterolemic rabbit represented atherosclerosis progression (x40). **A:** normal arterial appearance as shown for the normal diet control group (group I), **B:** initial atherosclerotic lesion characterized by lipid laden macrophage (foam cells), commonly seen in aliskiren treated group (group III), **C:** intermediate atherosclerotic lesion characterized by extracellular lipid pool. **D:** Advance atherosclerotic lesion characterized by core of extracellular lipid and **E:** complicated atherosclerotic lesion characterized by hemorrhagic thrombus. Both D&E were seen in the atherogenic group (group II).

normal, initial, intermediate, advance and complicated lesions (Figure 2). The median histopathological grade of

atherosclerotic changes was significantly different between all the 3 study groups. The median was highest in atherogenic control (advance) and lowest in the normal diet control (no abnormality). Aliskiren treated group was associated with a median aortic change (initial) that is significantly lower than the atherogenic control, see Figure 2.

Discussion

Previous studies showed that process of atherosclerosis development in human is very similar to that of rabbits and it is highly affected by cholesterol-rich diet [20]. The current study showed that feeding the rabbits with cholesterol rich diet for 8 weeks significantly improve their serum lipid profile (TC, TG, LDL-C and VLDL-C). However, HDL-C did not show a significant increase. Similar findings in serum lipids were obtained by using Licofelone and Simvastatin [21,22]. On the other hand, aliskiren trial showed no significant effect on serum lipids (TC, TG, LDL, VLDL and HDL), although it has been previously proven to be effective in preventing atherosclerotic plaque [12,23].

There are increasing evidence suggesting that enhanced oxidative stress plays a significant role in the development of cardiovascular complications [24,25]. Accordingly lipid peroxidation was measured in this study as a sensitive tool to assess lipid status. As MDA, an end product of polyunsaturated fatty acid oxygenation is reliable and commonly used biomarker for assessing lipid peroxidation [26], the measurement of MDA gives indirect evidence of LDL oxidation. The present study showed that hypercholesterolemia is associated with an increase in the plasma level of lipid peroxidation product, suggesting an increase in the level of oxygen free radicals. A similar finding were reported by other study [27].

Hypercholesterolemia could increase the levels of reactive oxygen species (ROS) through stimulation of polymorphonuclear leukocytes (PMNLs) and activation of endothelial cells [28]. Plasma levels of platelet activating factor (PAF) are elevated in hypercholesterolemia [29], PAF is known to stimulate granulocytes to release cytokines such as TNF- α [30] which stimulates nicotinamide adenine dinucleotide phosphate oxidase (NADPH-oxidase) in the endothelial cells to generate ROS [31] and INF- γ [32] which activate granulocytes to generate ROS [33]. In addition hypercholesterolemia increases synthesis of arachidonic acid and prostaglandins [34]. ROS generation is increased during synthesis of prostaglandins [35].

Aliskiren has favourable effect on GSH but the plasma level of GSH remains not significantly higher than that of AC group. Best to our knowledge, there were no currently available reports on the effect of aliskiren on GSH in hypercholesterolemic rabbit. However, Toshio *et al.*, in 2008 demonstrated that aliskiren significantly improve oxidation status in hypercholesterolemic rabbit [12]. The result of this study revealed that aliskiren significantly reduced lipid peroxidation as evident by significant reduction in plasma MDA this finding was in disagree with

Hong Lu *et al.*, in 2008, who reported that aliskiren don't have any effect on macrophage lipoxygenase expression and serum MDA [13].

The inflammatory process in the atherosclerotic artery may lead to increased blood levels of inflammatory cytokines and other acute-phase reactants [13]. In our study we demonstrated an elevation in plasma hs-CRP in cholesterol fed rabbit the same finding was observed by other studies [36,37]. CRP has been thought to be solely synthesized in the liver after stimulation by cytokines, such as IL-6 and TNF- α [38]. Previous studies have found that dietary high cholesterol intake can increase the productions of atherogenic inflammatory cytokines such as IL-6 and TNF α [39,40]. In addition Daqing *et al.*, in 2007 reveal that hypercholesterolemia may induce CRP secretions in adipocytes through reducing the expression of peroxisome proliferator-activated receptor (PPAR)- γ [37].

Our immunohistochemical analysis showed that VCAM-1, MCP-1, TNF-alpha and IL-17 expression is upregulated under hypercholesterolemic conditions, similar finding were observed by other studies [41-44]. Aliskiren favourably affecting plasma hs-CRP, furthermore our immunohistochemical analysis show that aliskiren significantly reduced the expression of all vascular inflammatory parameters that use in this study.

The anti-inflammatory effect of aliskiren has been supported by many researches, Jun *et al.*, in 2009 demonstrated that renin inhibition by aliskiren significantly reduced the expression of VCAM-1 and ICAM in injured arteries, also he found that the expression of NF- κ B, was attenuated by aliskiren [45]. In addition, Alessandra *et al.*, showed that aliskiren down-regulates TNF- α -stimulated TF expression in HUVECs. Also she was found that renin inhibition by aliskiren abrogates TNF- α -mediated stimulation of the coagulation pathway in HUVECs [46].

Although there are no current data about the effect of aliskiren on IL-17, but we suggest that the mechanism by which aliskiren attenuate inflammatory markers involve inhibition of angiotensin II which regulates the expression of adhesion molecules, cytokines, chemokines, and growth factor secretion within the arterial wall [47].

The current study revealed that rabbits fed on atherogenic diet produced marked hypercholesterolemia and advanced atherosclerotic lesion. These finding was in agreement with other researches [49-50]. The severe hypercholesterolemia, enhanced oxidative stress, and inflammation are the possible contributors for the development and progression of atherosclerosis. These finding was in agreement with other researches [12,23,51]. This favourable effect of aliskiren may be mediated through inhibition of angiotensin II which is considered as the main pro-atherosclerotic mediator [47].

To our knowledge, this is the first study that focuses on illustrating the effects of aliskiren on atherosclerosis progression through studying various markers of oxidative stress/ antioxidant (as manifested by lipid peroxidation; MDA and GSH); anti-inflammatory markers (hs-CRP, TNF- α and IL-17); immunohistochemical markers (VCAM-1 & MCP-1) and

histopathological examination of atherosclerotic changes.

Conclusions

From the above data we can conclude that aliskiren is helpful in reducing lipid peroxidation, systemic inflammation and aortic expression of inflammatory markers used in this study and hence reduces the progression of atherosclerotic plaque changes.

Competing interests

The Authors declare that they have no competing interests.

Publication history

Received: 26-Nov-2012 Revised: 08-Feb-2013

Accepted: 15-Mar-2013 Published: 19-Mar-2013

Reference

1. Anderson TJ: **Assessment and treatment of endothelial dysfunction in humans.** *J Am Coll Cardiol* 1999, **34**:631-8. | [Article](#) | [PubMed](#)
2. Helft G, Worthley SG, Fuster V, Zaman AG, Schechter C, Osende JI, Rodriguez OJ, Fayad ZA, Fallon JT and Badimon JJ: **Atherosclerotic aortic component quantification by noninvasive magnetic resonance imaging: an *in vivo* study in rabbits.** *J Am Coll Cardiol* 2001, **37**:1149-54. | [Article](#) | [PubMed](#)
3. Barrabes JA and Mirabet M: **[Neovascularization in atherosclerotic lesions: homeostatic response or mechanism of progression of the disease?].** *Rev Esp Cardiol* 2003, **56**:947-8. | [Article](#) | [PubMed](#)
4. Hansson GK: **Inflammation, atherosclerosis, and coronary artery disease.** *N Engl J Med* 2005, **352**:1685-95. | [Article](#) | [PubMed](#)
5. Lee H, Shi W, Tontonoz P, Wang S, Subbanagounder G, Hedrick CC, Hama S, Borromeo C, Evans RM, Berliner JA and Nagy L: **Role for peroxisome proliferator-activated receptor alpha in oxidized phospholipid-induced synthesis of monocyte chemotactic protein-1 and interleukin-8 by endothelial cells.** *Circ Res* 2000, **87**:516-21. | [Article](#) | [PubMed](#)
6. Leitinger N: **Oxidized phospholipids as modulators of inflammation in atherosclerosis.** *Curr Opin Lipidol* 2003, **14**:421-30. | [Article](#) | [PubMed](#)
7. Tabas I, Williams KJ and Boren J: **Subendothelial lipoprotein retention as the initiating process in atherosclerosis: update and therapeutic implications.** *Circulation* 2007, **116**:1832-44. | [Article](#) | [PubMed](#)
8. Moore KJ and Freeman MW: **Scavenger receptors in atherosclerosis: beyond lipid uptake.** *Arterioscler Thromb Vasc Biol* 2006, **26**:1702-11. | [Article](#) | [PubMed](#)
9. Ruiz-Ortega M, Lorenzo O, Ruperez M, Esteban V, Suzuki Y, Mezzano S, Plaza JJ and Egido J: **Role of the renin-angiotensin system in vascular diseases: expanding the field.** *Hypertension* 2001, **38**:1382-7. | [Article](#) | [PubMed](#)
10. Kuhnast S, van der Hoorn JW, van den Hoek AM, Havekes LM, Liau G, Jukema JW and Princen HM: **Aliskiren inhibits atherosclerosis development and improves plaque stability in APOE*3Leiden.CETP transgenic mice with or without treatment with atorvastatin.** *J Hypertens* 2012, **30**:107-16. | [Article](#) | [PubMed](#)
11. Duggan K: **Clinical implications of renin inhibitors.** *Aust Prescr* 2009, **32**:135-8. | [Pdf](#)
12. Imanishi T, Tsujioka H, Ikejima H, Kuroi A, Takarada S, Kitabata H, Tanimoto T, Muragaki Y, Mochizuki S, Goto M, Yoshida K and Akasaka T: **Renin inhibitor aliskiren improves impaired nitric oxide bioavailability and protects against atherosclerotic changes.** *Hypertension* 2008, **52**:563-72. | [Article](#) | [PubMed](#)
13. Lu H, Rateri DL, Feldman DL, Jr RJ, Fukamizu A, Ishida J, Oesterling EG, Cassis LA and Daugherty A: **Renin inhibition reduces hypercholesterolemia-induced atherosclerosis in mice.** *J Clin Invest* 2008, **118**:984-93. | [Article](#) | [PubMed Abstract](#) | [PubMed Full Text](#)
14. Brown H and DiFrancesco D: **Voltage-clamp investigations of membrane currents underlying pacemaker activity in rabbit sino-atrial node.** *J Physiol* 1980, **308**:331-351. | [Pdf](#)
15. DiFrancesco D, Ferroni A, Mazzanti M and Tromba C: **Properties of the hyperpolarizing-activated current (I_h) in cells isolated from the rabbit sino-atrial node.** *J Physiol* 1986, **377**:61-88. | [Article](#) | [PubMed Abstract](#)

- | [PubMed Full Text](#)
16. Hayashi T, Fukuto JM, Ignarro LJ and Chaudhuri G: **Basal release of nitric oxide from aortic rings is greater in female rabbits than in male rabbits: implications for atherosclerosis.** *Proc Natl Acad Sci U S A* 1992, **89**:11259-63. | [Article](#) | [PubMed Abstract](#) | [PubMed Full Text](#)
 17. Beutler E: **Glucose-6-phosphate dehydrogenase (G-6-PD) and 6-phosphogluconate dehydrogenase (6-PDG).** In: Beutler E. *Red cell metabolism: a manual of biochemical methods*. 2nd ed. New York: Grune & Stratton 1975, 66–69.
 18. Stary HC: **Natural history and histological classification of atherosclerotic lesions: an update.** *Arterioscler Thromb Vasc Biol* 2000, **20**:1177-8. | [Article](#) | [PubMed](#)
 19. Chen YH, Lin SJ, Chen JW, Ku HH and Chen YL: **Magnolol attenuates VCAM-1 expression *in vitro* in TNF-alpha-treated human aortic endothelial cells and *in vivo* in the aorta of cholesterol-fed rabbits.** *Br J Pharmacol* 2002, **135**:37-47. | [Article](#) | [PubMed Abstract](#) | [PubMed Full Text](#)
 20. Yanni AE: **The laboratory rabbit: an animal model of atherosclerosis research.** *Lab Anim* 2004, **38**:246-56. | [Article](#) | [PubMed](#)
 21. Vidal C, Gomez-Hernandez A, Sanchez-Galan E, Gonzalez A, Ortega L, Gomez-Gerique JA, Tunon J and Egido J: **Licofelone, a balanced inhibitor of cyclooxygenase and 5-lipoxygenase, reduces inflammation in a rabbit model of atherosclerosis.** *J Pharmacol Exp Ther* 2007, **320**:108-16. | [Article](#) | [PubMed](#)
 22. Hernandez-Presa MA, Ortega M, Tunon J, Martin-Ventura JL, Mas S, Blanco-Colio LM, Aparicio C, Ortega L, Gomez-Gerique J, Vivanco F and Egido J: **Simvastatin reduces NF-kappaB activity in peripheral mononuclear and in plaque cells of rabbit atheroma more markedly than lipid lowering diet.** *Cardiovasc Res* 2003, **57**:168-77. | [Article](#) | [PubMed](#)
 23. Nussberger J, Aubert JF, Bouzourene K, Pellegrin M, Hayoz D and Mazzolai L: **Renin inhibition by aliskiren prevents atherosclerosis progression: comparison with irbesartan, atenolol, and amlodipine.** *Hypertension* 2008, **51**:1306-11. | [Article](#) | [PubMed](#)
 24. Aso Y: **Cardiovascular disease in patients with diabetic nephropathy.** *Curr Mol Med* 2008, **8**:533-43. | [Article](#) | [PubMed](#)
 25. Rojas A, Mercadal E, Figueroa H and Morales MA: **Advanced Glycation and ROS: a link between diabetes and heart failure.** *Curr Vasc Pharmacol* 2008, **6**:44-51. | [Article](#) | [PubMed](#)
 26. Sheu JY, Ku HP, Tseng WC, Chen MT, Tsai LY and Huang YL: **Determination of thiobarbituric acid adduct of malondialdehyde using on-line microdialysis coupled with high-performance liquid chromatography.** *Anal Sci* 2003, **19**:621-4. | [Article](#) | [PubMed](#)
 27. Prasanna G and Purnima A: **Protective Effect of Leaf Extract of Trichilia connaroides on hypercholesterolemia Induced Oxidative Stress.** *International Journal of Pharmacology* 2011 **7**: 106-112. | [Pdf](#) |
 28. Prasad K and Kalra J: **Oxygen free radicals and hypercholesterolemic atherosclerosis: effect of vitamin E.** *Am Heart J* 1993, **125**:958-73. | [Article](#) | [PubMed](#)
 29. Croft KD, Beilin LJ, Vandongen R, Rouse I and Masarei J: **Leukocyte and platelet function and eicosanoid production in subjects with hypercholesterolaemia.** *Atherosclerosis* 1990, **83**:101-9. | [Article](#) | [PubMed](#)
 30. Ascer E, Bertolami MC, Venturinelli ML, Buccheri V, Souza J, Nicolau JC, Ramirez JA and Serrano CV, Jr.: **Atorvastatin reduces proinflammatory markers in hypercholesterolemic patients.** *Atherosclerosis* 2004, **177**:161-6. | [Article](#) | [PubMed](#)
 31. Gertzberg N, Neumann P, Rizzo V and Johnson A: **NAD(P)H oxidase mediates the endothelial barrier dysfunction induced by TNF-alpha.** *Am J Physiol Lung Cell Mol Physiol* 2004, **286**:L37-48. | [Article](#) | [PubMed](#)
 32. Oubina MP, de las Heras N, Cediel E, Sanz-Rosa D, Aragoncillo P, Diaz C, Hernandez G, Lahera V and Cachofeiro V: **Synergistic effect of angiotensin-converting enzyme (ACE) and 3-hydroxy-3-methylglutaryl-CoA (HMG-CoA) reductase inhibition on inflammatory markers in atherosclerotic rabbits.** *Clin Sci (Lond)* 2003, **105**:655-62. | [Article](#) | [PubMed](#)
 33. Ellis TN and Beaman BL: **Interferon-gamma activation of polymorphonuclear neutrophil function.** *Immunology* 2004, **112**:2-12. | [Article](#) | [PubMed Abstract](#) | [PubMed Full Text](#)
 34. Prasad K: **Dietary flax seed in prevention of hypercholesterolemic atherosclerosis.** *Atherosclerosis* 1997, **132**:69-76. | [Article](#) | [PubMed](#)
 35. Panganamala RV, Sharma HM, Heikkila RE, Geer JC and Cornwell DG: **Role of hydroxyl radical scavengers dimethyl sulfoxide, alcohols and methional in the inhibition of prostaglandin biosynthesis.** *Prostaglandins* 1976, **11**:599-607. | [Article](#) | [PubMed](#)
 36. Sun H, Koike T, Ichikawa T, Hatakeyama K, Shiomi M, Zhang B, Kitajima S, Morimoto M, Watanabe T, Asada Y, Chen YE and Fan J: **C-reactive protein in atherosclerotic lesions: its origin and pathophysiological significance.** *Am J Pathol* 2005, **167**:1139-48. | [Article](#) | [PubMed Abstract](#) | [PubMed Full Text](#)
 37. Zhang D, Che D, Zhao S and Sun Y: **Effects of atorvastatin on C-reactive protein secretions by adipocytes in hypercholesterolemic rabbits.** *J Cardiovasc Pharmacol* 2007, **50**:281-5. | [Article](#) | [PubMed](#)
 38. Moshage HJ, Roelofs HM, van Pelt JF, Hazenberg BP, van Leeuwen MA, Limburg PC, Aarden LA and Yap SH: **The effect of interleukin-1, interleukin-6 and its interrelationship on the synthesis of serum amyloid A and C-reactive protein in primary cultures of adult human hepatocytes.** *Biochem Biophys Res Commun* 1988, **155**:112-7. | [Article](#) | [PubMed](#)
 39. Han SN, Leka LS, Lichtenstein AH, Ausman LM, Schaefer EJ and Meydani SN: **Effect of hydrogenated and saturated, relative to polyunsaturated, fat on immune and inflammatory responses of adults with moderate hypercholesterolemia.** *J Lipid Res* 2002, **43**:445-52. | [Article](#) | [PubMed](#)
 40. Rahman SM, Van Dam AM, Schultzberg M and Crisby M: **High cholesterol diet results in increased expression of interleukin-6 and caspase-1 in the brain of apolipoprotein E knockout and wild type mice.** *J Neuroimmunol* 2005, **169**:59-67. | [Article](#) | [PubMed](#)
 41. Nakashima Y, Raines EW, Plump AS, Breslow JL and Ross R: **Upregulation of VCAM-1 and ICAM-1 at atherosclerosis-prone sites on the endothelium in the ApoE-deficient mouse.** *Arterioscler Thromb Vasc Biol* 1998, **18**:842-51. | [Article](#) | [PubMed](#)
 42. Iiyama K, Hajra L, Iiyama M, Li H, DiChiara M, Medoff BD and Cybulsky MI: **Patterns of vascular cell adhesion molecule-1 and intercellular adhesion molecule-1 expression in rabbit and mouse atherosclerotic lesions and at sites predisposed to lesion formation.** *Circ Res* 1999, **85**:199-207. | [Article](#) | [PubMed](#)
 43. Niemann-Jonsson A, Dimayuga P, Jovinge S, Calara F, Ares MP, Fredrikson GN and Nilsson J: **Accumulation of LDL in rat arteries is associated with activation of tumor necrosis factor-alpha expression.** *Arterioscler Thromb Vasc Biol* 2000, **20**:2205-11. | [Article](#) | [PubMed](#)
 44. Smith E, Prasad KM, Butcher M, Dobrian A, Kolls JK, Ley K and Galkina E: **Blockade of interleukin-17A results in reduced atherosclerosis in apolipoprotein E-deficient mice.** *Circulation* 2010, **121**:1746-55. | [Article](#) | [PubMed Abstract](#) | [PubMed Full Text](#)
 45. Ino J, Kojima C, Osaka M, Nitta K and Yoshida M: **Dynamic observation of mechanically-injured mouse femoral artery reveals an antiinflammatory effect of renin inhibitor.** *Arterioscler Thromb Vasc Biol* 2009, **29**:1858-63. | [Article](#) | [PubMed](#)
 46. Del Fiorentino A, Cianchetti S, Celi A and Pedrinelli R: **Aliskiren, a renin inhibitor, downregulates TNF-alpha-induced tissue factor expression in HUVECS.** *J Renin Angiotensin Aldosterone Syst* 2010, **11**:243-7. | [Article](#) | [PubMed](#)
 47. Graninger M, Reiter R, Drucker C, Minar E and Jilka B: **Angiotensin receptor blockade decreases markers of vascular inflammation.** *J Cardiovasc Pharmacol* 2004, **44**:335-9. | [Article](#) | [PubMed](#)
 48. Cavallini DC, Bedani R, Bomdespacho LQ, Vendramini RC and Rossi EA: **Effects of probiotic bacteria, isoflavones and simvastatin on lipid profile and atherosclerosis in cholesterol-fed rabbits: a randomized double-blind study.** *Lipids Health Dis* 2009, **8**:1. | [Article](#) | [PubMed Abstract](#) | [PubMed Full Text](#)
 49. Negis Y, Aytan N, Ozer N, Ogru E, Libinaki R, Gianello R, Azzi A and Zingg JM: **The effect of tocopherol phosphates on atherosclerosis progression in rabbits fed with a high cholesterol diet.** *Arch Biochem Biophys* 2006, **450**:63-6. | [Article](#) | [PubMed](#)
 50. Padoveze AF, Maniero F, Oliveira TV, Vitorio TS, Couto RD and Maranhao RC: **Effect of a cholesterol-rich diet on the metabolism of the free and esterified cholesterol components of a nanoemulsion that resembles LDL in rabbits.** *Braz J Med Biol Res* 2009, **42**:172-8. | [Article](#) | [PubMed](#)
 51. Verma S and Gupta MK: **Aliskiren improves nitric oxide bioavailability and limits atherosclerosis.** *Hypertension* 2008, **52**:467-9. | [Article](#) | [PubMed](#)